https://doi.org/10.33266/2070-1004-2022-2-42-46
UDC 612.82:614.2:616.8-005

Review report

EDEMA-LIKE LESIONS: ACCORDING TO MAGNETIC RESONANCE IMAGING OF THE KNEE JOINT IN HIGHLY QUALIFIED ATHLETES

M.N.Velichko[1], A.M.Belyakova[1], A.Y.Terskov[1], A.S.Umnikov[1]

[1] State Research Center – Burnasyan Federal Medical Biophysical Center of Federal Medical Biological Agency, Moscow, Russian Federation

Abstract. *The aim of the study* is to substantiate the relevance of the problem of edematous changes in knee joint bones in highly qualified athletes.
Materials and research methods. Materials of the study — relevant literature on edema-like magnetic resonance changes of knee joint bones in highly qualified athletes.
Results of the study and their analysis. Magnetic resonance imaging plays a key role in the differential diagnosis of edema-like bone injuries. It is important to correlate magnetic resonance imaging findings with anamnestic history. In athletes, the peculiarities of diagnosis and treatment of edema-like bone conditions are related to the need to take into account athlete-specific conditions, such as the "athlete's triad", and to comply with anti-doping legislation.
It is concluded that it is fundamental to treat the underlying disease that caused the local metabolic disorder in the bone, while techniques aimed at local reduction of the pressure in the bone and at bone metabolism improvement can be used as a supplement. An important factor is the ability of bone tissue to self-repair, which should be taken into account when choosing a treatment method.

Key words: *anterior cruciate ligament rupture, bone marrow edema, doping, magnetic resonance imaging, edema-like injuries, highly qualified athletes, knee injury, osteopenia, osteoporosis, stress fracture*

Conflict of interest. The authors declare no conflict of interest

For citation: Velichko M.N., Belyakova A.M., Terskov A.Yu., Umnikov A.S. Edema-Like Lesions: According to Magnetic Resonance Imaging of the Knee Joint in Highly Qualified Athletes. *Meditsina Katastrof* = Disaster Medicine. 2022;2:42-46 (In Russ.). https://doi.org/10.33266/2070-1004-2022-2-42-46

https://doi.org/10.33266/2070-1004-2022-2-42-46
УДК 612.82:614.2:616.8-005

Обзорная статья

ОТЁКОПОДОБНЫЕ ПОВРЕЖДЕНИЯ: ПО ДАННЫМ МАГНИТНО-РЕЗОНАНСНОЙ ТОМОГРАФИИ КОЛЕННОГО СУСТАВА У СПОРТСМЕНОВ ВЫСОКОЙ КВАЛИФИКАЦИИ

М.Н.Величко[1], А.М.Белякова[1], А.Ю.Терсков[1], А.С.Умников[1]

[1] ФГБУ «ГНЦ – Федеральный медицинский биофизический центр им. А.И. Бурназяна» ФМБА России, Москва, Россия

Резюме. *Цель исследования* – обосновать актуальность проблемы возникновения отёкоподобных изменений костей коленного сустава у спортсменов высокой квалификации.
Материалы и методы исследования. Материалы исследования – релевантная литература по отёкоподобным магнитно-резонансным (МР) изменениям костей коленного сустава у спортсменов высокой квалификации.
Результаты исследования и их анализ. Магнитно-резонансная томография (МРТ) играет ключевую роль в дифференциальной диагностике отёкоподобных повреждений кости. При этом важно соотносить результаты МРТ с анамнезом. У спортсменов особенности диагностики и лечения отёкоподобных состояний кости связаны с необходимостью учёта специфичных для атлетов состояний, таких, например, как «триада спортсменки», и соблюдения антидопингового законодательства.
Сделаны выводы, что принципиальным является лечение основного заболевания, послужившего причиной нарушения местных обменных процессов в кости, а в качестве дополнения могут использоваться методики, направленные на местное снижение давления в кости и улучшение костного метаболизма. Важным фактором является также способность костной ткани к самовосстановлению, которую следует учитывать при выборе метода лечения.

Ключевые слова: *допинг, магнитно-резонансная томография, остеопороз, отёк костного мозга, остеопения, отёкоподобные повреждения, разрыв передней крестообразной связки, спортсмены высокой квалификации, стрессовый перелом, травма коленного сустава*

Конфликт интересов. Авторы статьи подтверждают отсутствие конфликта интересов

Для цитирования: *Величко М.Н., Белякова А.М., Терсков А.Ю., Умников А.С.* Отёкоподобные повреждения: по данным магнитно-резонансной томографии коленного сустава у спортсменов высокой квалификации // Медицина катастроф. 2022. №2. С. 42-46. https://doi.org/10.33266/2070-1004-2022-2-42-46

Contact information:
Maksim N. Velichko – Head of Department of Sports Traumatology and Sports Medicineof Burnasyan FMBC of FMBA of Russia
Address: 46, Zhivopisnaya str., Moscow, 123098, Russia
Phone: +7 (915) 069-42-46
E-mail: maxveldoc@yandex.ru

Контактная информация:
Величко Максим Николаевич – зав. отделением спортивной травматологии и спортивной медицины ФМБЦ им. А.И. Бурназяна ФМБА России
Адрес: Россия, 123098, Москва, ул. Живописная, д. 46
Тел.: +7 (915) 069-42-46
E-mail: maxveldoc@yandex.ru

The aim of the study is to substantiate the relevance of the problem of edema-like changes in the knee joint bones in highly qualified athletes.

Objectives of the study:

1. To review the relevant literature on edema-like MR changes of the knee joint bones in highly qualified athletes.
2. To present current relevant classifications and diagnostic algorithms, including differential, of edema-like bone changes.
3. To review the main clinical variants of edema-like changes in highly qualified athletes.
4. To characterize the peculiarities of the use of the proposed classifications and algorithms in the context of practical work on medical and biological support of highly qualified athletes.
5. To formulate approaches to the management of athletes with bone swelling of various etiology taking into account the basics of modern anti-doping legislation.

Materials and research methods. Materials of the study — relevant literature on edema-like magnetic resonance changes of knee joint bones in highly qualified athletes.

Results of the study and their analysis. The term "bone marrow edema" was first introduced into the radiological community by Wilson et al. in 1988. [1]. The authors originally used it to refer to the hyperintense on T2-magnetic resonance MR signal in patients with knee and hip joint pain. Standard radiographs showed nonspecific local osteopenia or appeared normal. The co-authors referred to this condition as "bone marrow edema" due to the lack of a better term at the time. However, it should be understood that histologically the focus of the so-called "edema" reveals very heterogeneous abnormalities: necrosis, bone marrow fibrosis and trabecular structure disorders, increased number of microvessels. Although the "edema" itself may be small. Thus, the term "bone marrow edema" is not correct. Based on current views, we believe that in the context of the magnetic resonance imaging (MRI) discussion, it is better to call the entire group of these conditions "edema-like lesions". And the essence of the process taking place in the bone should be called "bone marrow lesion" [2]. For simplicity, the authors will use the terms "edema-like lesion" and "bone marrow lesion" interchangeably.

Classification of "edema-like changes" of knee bones

1. Traumatic edema — edema due to trauma or microfracture in combination with or without osteoporosis; postoperative edema; complex regional pain syndrome — CRPS.

2. Septic edema — edema due to osteomyelitis or infectious arthritis.

3. Primary inflammatory edema — edema from arthritis of peripheral joints; spondylitis/sacroileitis; bone edema from enthesitis, chronic nonbacterial osteomyelitis (ang. "CNO")

4. Mechanical/degenerative. Swelling in osteoarthritis, insertional tendinopathy, (osteo)chondral defects; changes/instability in stressful bone.

5. Neoplastic edema — edema in primary or secondary benign or malignant bone tumors.

6. Ischemic/neurogenic edema — edema in avascular necrosis of bone, Charcot neuroarthropathy.

7. Metabolic edema — edema in primary osteoporosis, secondary osteoporosis, and osteopathies.

8. Diagnosis of exclusion — bone marrow edema syndrome (BMES).

In everyday practice we are guided by the classification of "edema-like changes" proposed in 2020 by a working group from Ludwig Maximilian University [3]. The classification is based on the probable cause of the "edema". This allows, from the authors' point of view, to form a rational approach to the tactics of patient management. In our daily work, we follow similar tactics of treatment and diagnostic routing of patients, based on this classification.

It should be said that our adopted working classification and approach to the treatment of osteonecrosis do not contradict the draft clinical guidelines of the Russian Medical Association for Osteonecrosis, the Russian Association of Traumatologists and Orthopedists, and the Association of Rheumoorthopedists (2020) [4].

"Edema-like lesions" and their variations are only MR manifestation of the evolution of some pathological process in bone. "Edema" may be the beginning or the end of a process or a stage preceding osteonecrosis. Osteonecrosis may or may not be accompanied by the formation of an osteochondral defect. If the reparative capacity of the bone successfully withstands the damaging factors, the process in the bone is completed without osteonecrosis formation. If reparative processes are insufficient, the natural outcome of such a condition may be bone necrosis in various variants [5].

Causes of osteonecrosis

- Normal bone — normal bone remodeling and repair.
- Bone damage — vascular, mechanical/traumatic, inflammatory, metabolic, etc.
- Disturbance of metabolic processes in bone tissue — local increase in bone metabolism, increased intra-bone pressure, overloading/microfractures.
- "Swelling" of bone marrow — increase in intra-bone pressure /compartment syndrome.
- Reparative mechanisms: if adequate — gradual resolution; if inadequate — bone necrosis.

Taking into account the above, we talk about osteochondral defects in the context of the fact that they can be the outcome (however, far from being obligatory) of various processes in the bone manifested by "edema-like" changes. Although there can be only one outcome — articular surface defect, the preceding changes in the bone can have different causes and, therefore, require different approaches to active monitoring and treatment.

In the context of observation of athletes, another phenomenon that may accompany bone swelling should be kept in mind: stress fracture [6].

As for stress fractures, it seems rational to divide them into 2 groups: fatigue fractures and bone insufficiency fractures. In the case of athletes, we usually talk about the

excessive load on the healthy bone, due to which it undergoes reciprocal changes. In patients with osteoarthritis, we're talking about a fracture due to the bone breaking under no more than a daily load. Both are stress fractures [7].

The MRI protocol for investigating "bone swelling" usually includes fat-suppressed sequences such as STIR or PDW FS in three planes, as well as T1-weighted sequences without contrast enhancement and with the introduction of gadolinium contrast. Fat-suppressed MRI images (STIR or PDW FS) clearly show bone marrow and soft tissue swelling and hemorrhage. In order to understand whether there is osteonecrosis or not, contrast needs to be injected. The introduction of contrast rapidly enhances the bone swelling signal in the MR images. At the same time, there is no enhancement of the osteonecrosis area with this contrast (Fig. 1).

Such diagnosis is possible because as early as in 2001, a group of authors confirmed that osteonecrosis leads to a sharp delay of venous outflow in the affected area. Intraosseous injected contrast was washed out from the zone of necrosis after 17 min, whereas from the femoral condyle affected by arthrosis but without necrosis — after 5 min. Importantly, the study also showed an almost twofold increase in intraosseous pressure in the femoral condyle with the outcome of the edema-like process in osteonecrosis. The authors believe that such an increase is a natural consequence of venous thrombosis with impaired outflow tract. However, it can hardly be said that any edema-like change on MRI is accompanied by the same significant pressure increase. Different diseases underlie the phenomenon of edema-like changes. The described pressure increase characteristic of osteonecrosis does not necessarily accompany, for example, painless transient bone marrow edema [1].

According to some authors, more sensitive in the differential diagnosis of edema and osteonecrosis is perfusion MRI (DCE MRI), in which the plasma flow and the average time of its passage through a certain volume are determined numerically.

To summarize, we can say that "edema-like" changes and their variations are a natural manifestation of the evolution of pathological processes in bone. "Swelling" accompanies the local disturbance of metabolic processes in bone tissue caused by different reasons. If reparative capabilities of bone tissue successfully resist the damaging factors, the process in bone resolves without osteonecrosis formation. If the reparative processes are insufficient, the natural outcome of such a condition can be a stress fracture or bone necrosis in one way or another. Osteonecrosis may or may not be accompanied by the formation of a free bone fragment.

Treatment

Given that there may be different processes behind the swelling-like changes in the bone, treatment can also vary greatly depending on the cause of the swelling. Moreover, before proceeding to medication, and even to surgical treatment, it is necessary to understand the likelihood of self-healing.

Earlier, we gave the classification of bone edema that we use. According to this classification, we will talk about only two types of bone edema — traumatic and non-traumatic. Obviously, traumatic bone swelling is more common in athletes. Let us consider a habitual tear of the anterior cruciate ligament, and use it as an example to trace the evolution of edema — Fig. 2 [8].

The natural development of posttraumatic bone edema is best studied exactly after anterior cruciate ligament trauma. It is known that such edemas occur in 68-98% of cases and the external condyle of the tibia is more frequently injured [9].

If you turn to the prospect of 5 years or more, the probability of detecting serious osteochondral changes of the knee joint will strongly depend on the size of the initial swelling. For the external condyle of the femur and tibia, the probability of developing such lesions when the swelling spreads to 100% of the area can reach 74% and 32%, respectively, on MRI slices. Thus, in these cases, special attention should be paid to the mode of compliance with the load on the operated joint. In addition, there are studies proving the effectiveness of bisphosphonates and prostaglandins in athletes in these cases. Their use is possible, however, only off label and should, from our point of view, be reserved for cases involving more than 100% of the cut area of the external condyles of the tibia or femur — Fig. 3 [10].

It is important to understand that with the resolution of the edema, the underlying cartilage lesion may continue to exist. Fig. 4 shows an example of bone edema regression according to MRI data in standard sequences. Fig. 5 is color MR imaging data of the same area. The red areas are areas of damaged cartilage that persist for more than one or two years. This may be an important argument for prescribing supportive treatment, such as chondroprotectors, to athletes after a ligament injury [11].

To summarize the approach to the management of patients with "traumatic edema" we can say the following. In most cases, a stabilizing surgery with a controlled loading dosing regimen is sufficient for complete resolution of the "edema". However, long-term preservation of chondral changes in the edema zone requires chondroprotective treatment with hyaluronic acid or bioorthopedic

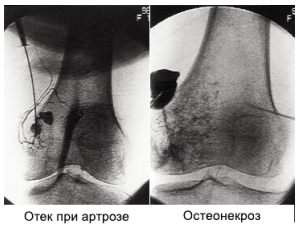

Рис. 1. МРТ с контрастированием. Слева: при внутрикостном введении – прокрашивание русла и выведение контраста через 5 мин Справа: при внутрикостном введении – нет прокрашивания венозного русла. Выведение контраста через 17 мин
Fig. 1. Magnetic resonance imaging with contrast.
With intraosseous administration, staining of the bed and removal of contrast after 5 minutes (left).
With intraosseous administration, there is no staining of the venous bed. Contrast removal after 17 min (right)

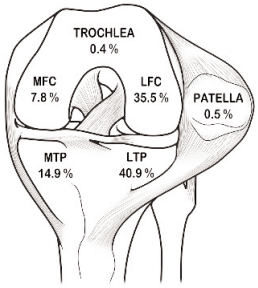

Рис. 2. Вероятность отёка кости после травмы ПКС в различных сегментах сустава
Fig. 2. Probability of bone edema after ACL injury in various joint segments

preparations. Extensive swelling that extends beyond the condyle may require bisphosphonates and Iloprost off label and only approved substances (some bisphosphonates are prohibited substances).

Stress fractures

Basically, all stress fractures can be divided into 2 subtypes: high risk and low risk of complications. Back in 2015, a classification of stress fractures was proposed, implying the timing of bone unloading corresponding to the severity of the fracture. Thus, at stages 1 to 2, the unloading time of the affected segment is about 3 weeks; at stages 3 to 4, it is from 6 to 16 weeks - Table [12–14].

Of the non-traumatic factors, it is necessary to elaborate on the most common cause of metabolic "bone swelling" — the "female athlete's triad". In the most simplified form, these are interrelated eating disorders (anorexia), amenorrhea, and osteoporosis. In sports and beyond, this is a very topical problem. Treatment of this condition may require medications such as antidepressants in addition to standard bone metabolism maintenance regimens.

A special diagnostic problem is caused by edema accompanying "fatigue" fractures against the background of subchondral bone strength insufficiency, which occurs in about 3% of cases. The medial compartment is more frequently involved. Meniscus tears — radial or root tears — occur in 76-94% of patients [6]. The treatment of these conditions is as follows. Since these conditions are often associated with meniscus damage, they are repaired if possible. If the condition occurred after meniscectomy, it is recommended to reduce the axial load for 3-4 weeks or more. All patients in the nontraumatic group and in the subgroup of non-septic edemas undergo a CT scan to clarify the nature and extent of the process (presence of fracture).

If primary osteoporosis is a probable concomitant condition of edema, it should be treated first in order to prevent progression of the process. If the underlying condition is secondary osteoporosis, treatment should involve correction of pathology such as vitamin D deficiency, diabetes mellitus, etc.

To summarize, we can say the following. The following drugs and methods are suggested in the current literature for the treatment of bone swelling:

1. Unloading for 3-6 weeks or more.
2. Non-steroidal anti-inflammatory drugs — situationally.
3. Wearing a brace that unloads the involved compartment.
4. Bisphosphonates.
5. Monoclonal antibodies (Dinosumab).

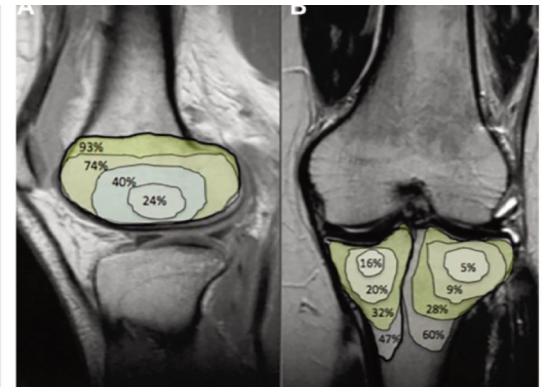

Рис. 3. Вероятность развития хондральных повреждений III-IV ст. через 5 лет после травм ПКС
Fig. 3. The likelihood of developing chondral lesions III-IV st. 5 years after ACL injury

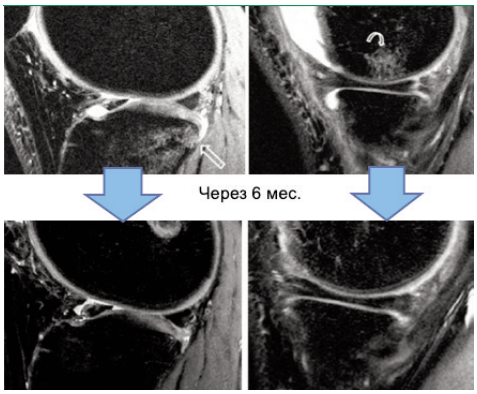

Рис. 4. Пример регресса отёка кости по данным МРТ
Fig. 4. An example of regression of bone edema according to MRI

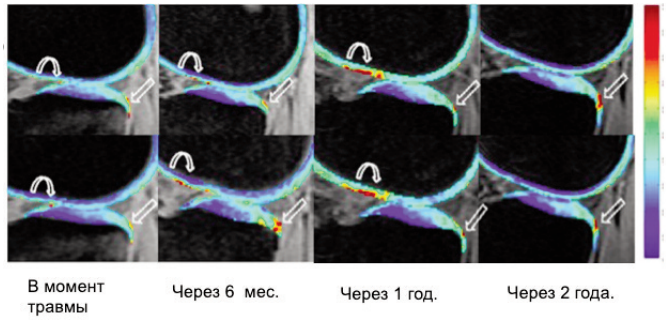

Рис. 5. Цветное МР-картирование. Красные зоны – участки поврежденного хряща
Fig. 5. Color MR mapping. Red zones - areas of damaged cartilage

Таблица

Модифицированная классификация стрессовых переломов E.Arendt

Стадия	Рентген	МРТ	Лечение
1-я	Норма	Патологический сигнал на STIR	Разгрузка – 3 нед
2-я	Норма	Патологический сигнал на STIR+T2	Разгрузка – 3–6 нед
3-я	Нечеткая линия или периостальная реакция	Линия на T1 и T2, но пока без повреждения кортикала	Разгрузка – 6–12 нед
4-я	Линия перелома или периостальная реакция	Четкая линия перелома на T1 и T2	Разгрузка – более 16 нед

6. Vitamin D preparations.
7. Iloprost.
8. Meniscus/osteotomy repair.
9. Subchondroplasty.
10. Decompression with the introduction of bioorthopedic preparations.

Treatment of the underlying disease, which caused the disturbance of local metabolic processes in the bone, is fundamental. As a supplement, local pressure reduction and improvement of bone metabolism can be performed. An important factor is also the ability of the bone tissue to self-repair, which should be considered when choosing the method of treatment. In sports, particular importance should be given to compliance with anti-doping legislation.

Conclusion

1. It is advisable to use etiological classifications of edema-like changes when choosing treatment tactics in athletes.

2. The main variants of edema-like changes in athletes are traumatic, and in a subgroup of non-traumatic — mechanical/degenerative, metabolic and transient bone edema.

3 The majority of edema-like injuries in athletes have a favorable prognosis.

(4) Female athletes aged 17-18 years are particularly at risk for stress edema formation. Older athletes require more attention.

5. When choosing treatment in athletes, peculiarities of anti-doping legislation should be taken into account.

REFERENCES / СПИСОК ИСТОЧНИКОВ

1. Wilson A.J., Murphy W.A., Hardy D.C., Totty W.G. Transient Osteoporosis: Transient Bone Marrow Edema? Radiology. 1988;167:757-60.
2. Sofat N. Drilling Down the Bone: Evaluating Bone Marrow Lesions in Osteoarthritis. EMJ. 2018;3;4:103-110.
3. Ludwig Maximilians University LMU. Consensus classification of BME. 2020.
4. Sebastian F. Baumbach, Vanessa Pfahler, Susanne Bechtold-Dalla Pozza, Isa Feist-Pagenstert, Julian Fümetz, Andrea Baur-Melnyk, Ulla C. Stumpf, Maximilian M. Saller, Andreas Straube, Ralf Schmidmaier and Jan Leipe. How We Manage Bone Marrow Edema – An Interdisciplinary Approach. J. Clin. Med. 2020;9;2:551. doi:10.3390/jcm9020551.
5. Sanjeev Patel. Primary Bone Marrow Oedema Syndromes. Rheumatology. 2014;53;5:785792 doi:10.1093.
6. Gorbachova T., Melenevsky Y., Cohen M., Cerniglia B.W. Osteochondral Lesions of the Knee: Differentiating the Most Common Entities at MRI. Radiographics. 2018;38;5:1478-1495. doi: 10.1148/rg.2018180044.
7. Mason R.W., Moore T.E., Walker C.W., Kathol M.H. Patellar Fatigue Fractures. Skeletal Radiol. 1996;5;4:329–332.
8. Uchio Y., Ochi M., Adachi N., et al. Intraosseous Hypertension and Venous Congestion in Osteonecrosis of the Knee. Clinical Orthopaedics and Related Research. 2001;384:217–223.
9. Filardo G., Andriolo L., et. al. Bone Bruise in Anterior Cruciate Ligament Rupture Entails a more Severe Joint Damage Affecting Joint Degenerative Progression. Knee Surgery, Sports Traumatology, Arthroscopy. 2019;27;1:44-59. doi: 10.1007/s00167-018-4993-4. Epub 2018 Jun 5.
10. Kia C., Cavanaugh Z., Gillis E., Dwyer C., Chadayammuri V., Muench L.N., Berthold D.P, Murphy M., Pacheco R., Arciero R.A. Size of Initial Bone Bruise Predicts Future Lateral Chondral Degeneration in ACL Injuries. A Radiographic Analysis. The Orthopaedic Journal of Sports Medicine. 2020;8;5:2325967120916834 DOI: 10.1177/2325967120916834.
11. Gong J., Pedoia V., Facchetti L., Link T.M., Ma C.B., Li X. Bone Marrow Edema-Like Lesions (BMELs) are Associated with Higher T1ρ and T2 Values of Cartilage in Anterior Cruciate Ligament (ACL)-Reconstructed Knees: a Longitudinal Study. Quant. Imaging. Med. Surg. 2016;6;6:661-670. doi: 10.21037/qims.2016.12.11.
12. Brown G.A., Stringer M.R., Arendt E.A. Stress Fractures of the Patella. Stress Fractures in Athletes. Eds Miller T., Kaeding C. Springer, Cham, 2015. https://doi.org/10.1007/978-3-319-09238-6_9.
13. Akhavan S., Martinkovich Stephen C., Kasik C., DeMeo Patrick J. Bone Marrow Edema, Clinical Significance, and Treatment Options: A Review. Journal of the American Academy of Orthopaedic Surgeons. 2020;28;20: p e888-e899. doi: 10.5435/JAAOS-D-20-00142.
14. Costa-Paz M., Muscolo D.L., Ayerza M., Makino A., Aponte-Tinao L. Magnetic Resonance Imaging Follow-Up Study of Bone Bruises Associated with Anterior Cruciate Ligament Ruptures. Arthroscopy. 2001;17;5:445–449.

Материал поступил в редакцию 06.04.22; статья принята после рецензирования 10.06.22; статья принята к публикации 23.06.22
The material was received 06.04.22; the article after peer review procedure 10.06.22; the Editorial Board accepted the article for publication 23.06.22