https://doi.org/10.33266/2070-1004- 2021-4-61-63
UDC 616-082:616-001:616.36

Short report

USE OF INNOVATIVE TECHNOLOGIES IN THE TREATMENT OF PATIENTS WITH SEVERE CONCOMITANT INJURY WITH LIVER DAMAGE: CLINICAL OBSERVATION

A.E.Voynovskiy [1,2], I.A.Semenenko [1,2], A.S. Kuptsov [2]

[1] City Clinical Hospital named after S.S. Yudin of the Moscow Department of Health, Moscow, Russian Federation
[2] I.M. Sechenov First Moscow State Medical University (Sechenov University), Moscow, Russian Federation

Abstract. Liver injury is one of the most common abdominal injuries in patients with severe trauma.
A total of 2988 patients with concomitant injuries were treated at the city clinical hospital named after S.S. Yudin during the period from 2010 to 2020, of which 371 (12.4%) were found to have closed abdominal trauma. Damage to the liver was revealed in 124 (33.4%) patients with closed abdominal trauma. The number of discharged patients was 78 (62,9%), lethal outcome — 46 patients (37,1%). The severity of injury according to ISS was (38,1±11,3) points. The development of innovative multimodal approaches, such as endovascular trauma and bleeding management (EVTM), as well as damage control tactics have significantly increased the likelihood of nonoperative treatment for individual patients.
A clinical observation is presented that allows to evaluate the effectiveness of innovative technologies in the treatment of patients with severe concomitant trauma with liver damage.

Key words: *closed abdominal trauma, innovative technologies, liver injury, non-surgical treatment of victims with severe concomitant trauma, polytrauma, X-ray endovascular treatment*

Conflict of interest. The authors declare no conflict of interest

For citation: Voynovskiy A.E., Novikov G.A., Semenenko I.A., Kuptsov A.S. Use of Innovative Technologies in the Treatment of Patients with Severe Concomitant Injury with Liver Damage. *Meditsina katastrof* = Disaster Medicine. 2021;4:61-63 (In Russ.). https://doi.org/10.33266/2070-1004-2021-4-61-63

https://doi.org/10.33266/2070-1004-2021-4-61-63
УДК 616-082:616-001:616.36

Краткое сообщение

ПРИМЕНЕНИЕ ИННОВАЦИОННЫХ ТЕХНОЛОГИЙ ПРИ ЛЕЧЕНИИ ПОСТРАДАВШИХ С ТЯЖЕЛОЙ СОЧЕТАННОЙ ТРАВМОЙ С ПОВРЕЖДЕНИЕМ ПЕЧЕНИ: КЛИНИЧЕСКОЕ НАБЛЮДЕНИЕ

А.Е.Войновский, И.А.Семененко, А.С.Купцов

[1] ГБУЗ «Городская клиническая больница им. С.С.Юдина Департамента здравоохранения города Москвы», Москва, Россия
[2] ФГАОУ ВО «Первый Московский государственный медицинский университет им. И.М.Сеченова» Минздрава России (Сеченовский Университет), Москва, Россия

Резюме. Отмечено, что травма печени – одно из наиболее частых повреждений органов брюшной полости у пациентов с тяжелыми сочетанными травмами. В 2010–2020 гг. в Городской клинической больнице им. С.С.Юдина проходили лечение 2988 пострадавших с сочетанной травмой, у 371 из них (12,4%) была выявлена закрытая травма живота, повреждения печени выявлены у 124 пациентов (33,4%). Выписаны 78 пациентов (62,9%), летальный исход – 46 пациентов (37,1%). Тяжесть травмы по ISS составила (38,1±11,3) баллов. Применение новых инновационных мультимодальных подходов, таких, как рентгенэндоваскулярное лечение травм и кровотечений (EVTM-endovascular trauma management), значительно повышает возможность безоперационного лечения (non-operative management) и улучшает его результаты.
Представлено клиническое наблюдение, позволяющее оценить эффективность применения инновационных технологий при лечении пострадавших с тяжелой сочетанной травмой с повреждением печени.

Ключевые слова: *безоперационное лечение, закрытая травма живота, инновационные технологии, повреждение печени, политравма, пострадавшие с тяжелой сочетанной травмой, рентгенэндоваскулярное лечение, тактика damage control*

Конфликт интересов. Авторы сообщения подтверждают отсутствие конфликта интересов

Для цитирования: *Войновский А.Е., Семененко И.А., Купцов А.С.* Применение инновационных технологий при лечении пострадавших с тяжелой сочетанной травмой с повреждением печени // Медицина катастроф. 2021. №4. С. 61-63. https://doi.org/10.33266/2070-1004-2021-4-61-63

Contact information:
Aleksandr E. Voynovskiy – Doctor. Sci. (Med.)Professor of the Department of Hospital Surgery No. 2, Deputy Chief Physician for Emergency Surgical Aid
Address: 4, Kolomenskiy proezd, Moscow, 115446, Russia
Phone: +7 (903) 968-28-56
E-mail: voinovsky@mail.ru

Контактная информация:
Войновский Александр Евгеньевич – доктор медицинских наук, профессор кафедры госпитальной хирургии №2, заместитель главного врача по экстренной хирургической помощи
Адрес: Россия, 115446, Москва, Коломенский проезд, 4
Тел.: +7 (903) 968-28-56
E-mail: voinovsky@mail.ru

The incidence of liver damage in closed abdominal trauma, according to various authors, ranges from 11.0% to 41.5%. Damage to the spleen is also often noted — 16.1–40.3%; less often kidney damage is detected — 7.1–18%; pancreas — 1.4–8.5%; small intestine — 19.6–37.8%; colon — 6.1-11.5%; Duodenal ulcer — 1.04-10.0%; bladder — 6.1-16.9%; mesentery — 10.7–31.0%; diaphragm — 2.0–3.0%; large vessels — 1.9–2.5% [1, 5].

From 2010 to 2020 in the city clinical hospital named after S.S. Yudin 2988 patients with concomitant trauma were treated, of which 371 (12.4%) had a closed abdominal trauma. Liver injuries were observed in 124 (33.4%) patients with closed abdominal trauma. 78 (62.9%) patients were discharged, 46 (37.1%) died. The severity of the injury according to the ISS was 38.1 + 11.3 points. According to the AAST injury scale, out of 124 patients: with I injuries. — 45 (36.2%), II — 49 (39.5%), III — 16 (13%), IV — 11 (8.9%), V — 3 (2.4%).

The development of new innovative multimodal approaches, such as endovascular trauma management (EVTM) and damage control tactics, have significantly increased the likelihood of non-operative management for individual patients [5]. This advanced strategy requires a multidisciplinary approach, comprehensive diagnostic testing, and 24/7 availability of equipment and services. This became possible in the last decade in our hospital thanks to the modernization of Moscow healthcare and the associated technological re-equipment, training of medical personnel, fast transportation of victims, introduction of the damage control concept into clinical practice. Those are the key conditions for a successful multidisciplinary approach to a victim with concomitant trauma (2, 3, 6).

In this regard, therapeutic and diagnostic tactics have radically changed: conservative therapy is indicated for all hemodynamically stable patients with any degree of isolated liver injury. With signs of ongoing bleeding on CT in combination with stable hemodynamics, endovascular embolization is necessary, which is effective in 50–94% of cases [7]. Obviously, the more severe the liver injury, the greater the risk of failure of non-surgical treatment. Ineffectiveness of endovascular embolization or recurrent bleeding is an indication for discontinuation of conservative therapy and for an emergency surgery. Non-operative management based on CT data helps to reduce mortality and cost of treatment [4].

This approach is illustrated by the following clinical example. 22 years old woman, was admitted to the hospital on an emergency basis on 02/04/2021 after falling from a height of the 9th floor with a diagnosis of Catatrauma (ISS 26 points): closed abdominal trauma with liver damage. Central intraparenchymal hematoma of the liver (AAST II). Closed head injury. Brain concussion. Closed complicated chest trauma: pneumomediastinum, bilateral pneumothorax, fracture of the left scapula body. Lung contusion. Contusion of soft tissues of the chest, extremities. Fracture of the body of the left scapula without displacement of fragments. Traumatic shock.

According to EFAST ultrasound: heterogeneous fluid accumulation in the right lobe of the liver measuring 54x52x54mm.

CT scan with intravenous contrast revealed an extensive lesion, with the formation of a hematoma, affecting the IV, VII, VIII segments of the liver with extravasation of contrast agent into arterial and venous phases (Pic. 1-2)

As a result of instrumental and laboratory examination no data was obtained for active intra-abdominal bleeding, the size of the hematoma corresponded to WSES I / AAST II, — it was decided to perform selective angiography followed by occlusion of the branch of the left hepatic artery (Pic. 3-4)

According to the data of ultrasound of the abdominal organs in dynamics, the hematoma size regressed. On the 6th day, the patient was discharged home in a satisfactory condition.

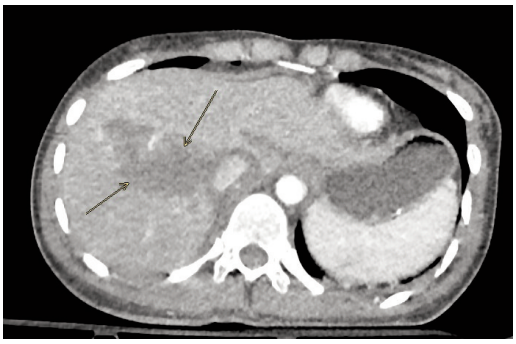

Рис. 1. Рис. 1. Компьютерная томография органов брюшной полости (ОБП) – артериальная фаза: гематома IV, VII, VIII сегментов печени с экстравазацией контрастного вещества
Fig. Abdominal CT (arterial phase): hematoma of IV, VII, VIII segments of the liver with contrast extravasation

Рис. 2. Компьютерная томография ОБП – венозная фаза: гематома IV, VII, VIII сегментов печени с экстравазацией контрастного вещества
Fig. 2. Abdominal CT (venous phase): hematoma of IV, VII, VIII segments of the liver with contrast extravasation

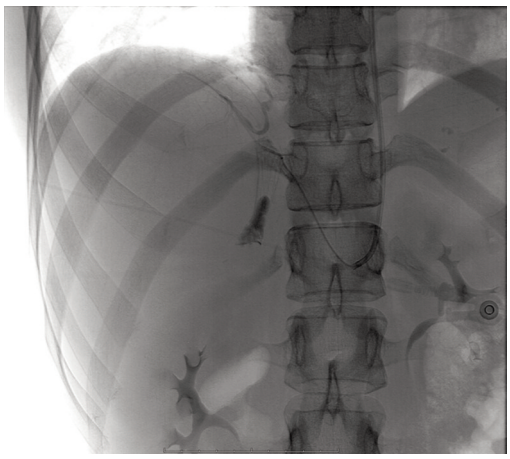

Рис. 3. Экстравазация контрастного вещества при селективной ангиографии левой ветви собственной печеночной артерии
Fig. 3. Contrast extravasation during selective angiography of the left branch of the intrinsic hepatic artery

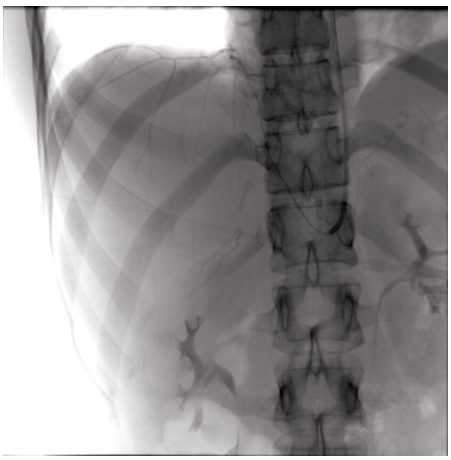

Рис. 4. Контрольная ангиография после эмболизации – отмечено отсутствие экстравазации.
Fig. 4. Control angiography after embolization — no extravasation observed

The treatment of liver injury is interdisciplinary. When feasible, non-surgical treatment (NOM) — angioembolization should be considered as the treatment of choice for liver injury with ongoing bleeding. A non-surgical method of treating patients with closed abdominal injuries is the preferred option for all hemodynamically stable patients (WSES I, AAST I - II), with moderate (WSES II, AAST III) and severe (WSES III, AAST IV - V) injuries in the absence of other internal injuries requiring surgical intervention [6,7]. A prerequisite for the non-surgical treatment of severe concomitant trauma with liver damage is the round-the-clock availability of all necessary examination and treatment methods, including angiography, EFAST ultrasound, computed tomography with intravenous contrast, and trained medical personnel.

REFERENCES

1. Kudryavtsev B.P., Savvin Yu.N., Krasnov S.A., Poyarkov A.M. Voynovskiy E.A., Efimenko N.A., Shabanov V.E. Clinical Guidelines for the Provision of Medical Care to Victims with Injuries of the Abdomen and Abdominal Organs in Emergency Situations. Moscow, VTsMK "Zashchita" Publ., 2015 (In Russ.).
2. Lyutov V.V., Voynovskiy A.E., Sushchenin A.A., Makhnovskiy A.I., Plaksa I.L., Raguzin E.V. The Experience of a Military Clinical Hospital in Providing Specialized Medical Care to Victims of Road Traffic Injuries. Disasters Medicine. 2013, № 2. P. 8-11 (In Russ.).
3. Obelchak I.S., Voynovskiy A.E., Shabalin A.Yu. The Role and Place of Computed Tomography in the Diagnosis of Traumatic Injuries of the Abdomen, Pelvis with gunshot wounds. Russian Electronic Journal of Radiation Diagnostics. 2013;3;2:112 (In Russ.).
4. Smolyar A.N. Closed Abdominal Trauma. Liver Damage. Part 1. Surgery. Journal Them. N.I. Pirogov. 2015;12;5. https://doi.org/10.17116/hirurgia2015125-13 (In Russ.).
5. Coimbra R., Ordonez C., Kluger Yo., Vega F., Ernest E. Moore, Biffl W., Peitzman E., Horer T., Fikri M. Abu-Zidan, Sartelli M., Gustavo P. Fraga, Cicuttin E., Ansaloni L., Michael W. Parra, Millán M., DeAngelis N., and the WSES Expert Panel. Liver Trauma. WSES 2020 Guidelines Federico Coccolini*. 2020. World Journal of Emergency Surgery. 2020;15;1; 24. https://doi.org/10.1186/s13017-020-00302-7
6. Letoublon C., Morra I., Chen Y., Monnin V., Voirin D., Arvieux C. Hepatic Arterial Embolization in the Management of Blunt Hepatic Trauma: Indications and Complications. J. Trauma. 2011. May;70(5):1032-6; discussion 1036-7. doi: 10.1097/TA.0b013e31820e7ca1.
7. New Hemostatic Device for Grade IV-V Liver Injury in Porcine Model: a Proof of Concept // World J Emerg Surg. 2019;Dec;16;14:58. doi: 10.1186/s13017-019-0277-7.

СПИСОК ИСТОЧНИКОВ

1. *Кудрявцев Б.П., Саввин Ю.Н., Краснов С.А., Поярков А.М., Войновский Е.А., Ефименко Н.А., Шабанов В.Е.* Клинические рекомендации по оказанию медицинской помощи пострадавшим с повреждениями живота и органов брюшной полости в чрезвычайных ситуациях. М.: ВЦМК «Защита», 2016. С. 69–90
2. *Лютов В.В., Войновский А.Е., Сущенин А.А., Махновский А.И., Плакса И.Л., Рагузин Е.В.* Опыт работы военного клинического госпиталя по оказанию специализированной медицинской помощи пострадавшим с автодорожной травмой // Медицина катастроф. 2013. № 2. С. 8-11.
3. *Обельчак И.С., Войновский А.Е., Шабалин А.Ю.* Роль и место компьютерной томографии в диагностике травматических повреждений живота, таза при огнестрельных ранениях // Российский электронный журнал лучевой диагностики. 2013. Т.3, № 2. С. 112.
4. *Смоляр А.Н.* Закрытая травма живота. Повреждения печени. Ч. 1 // Хирургия. Журнал им. Н.И.Пирогова. 2015. Т.12, № 5. https://doi.org/10.17116/hirurgia2015125-13.
5. *Coimbra R., Ordonez C., Kluger Yo., Vega F., Ernest E. Moore, Biffl W., Peitzman E., Horer T., Fikri M. Abu-Zidan, Sartelli M., Gustavo P. Fraga, Cicuttin E., Ansaloni L., Michael W. Parra, Millán M., DeAngelis N., and the WSES Expert Panel.* Liver Trauma. WSES 2020 Guidelines Federico Coccolini*. World Journal of Emergency Surgery. 2020. V.15. No. 1. 24 p. https://doi.org/10.1186/s13017-020-00302-7
6. *Letoublon C., Morra I., Chen Y., Monnin V., Voirin D., Arvieux C.* Hepatic Arterial Embolization in the Management of Blunt Hepatic Trauma: Indications and Complications // J. Trauma. 2011. May. No. 70. P. 1032-1037. doi: 10.1097/TA.0b013e31820e7ca1.
7. New Hemostatic Device for Grade IV-V Liver Injury in Porcine Model: a Proof of Concept // World J Emerg Surg. 2019. Dec. No. 16. P. 14:58. doi: 10.1186/s13017-019-0277-7.

The material was received 27.09.21; the article after peer review procedure 23.11.21; the Editorial Board accepted the article for publication 13.12.21
Материал поступил в редакцию 27.09.21; статья принята после рецензирования 23.11.21; статья принята к публикации 13.12.21